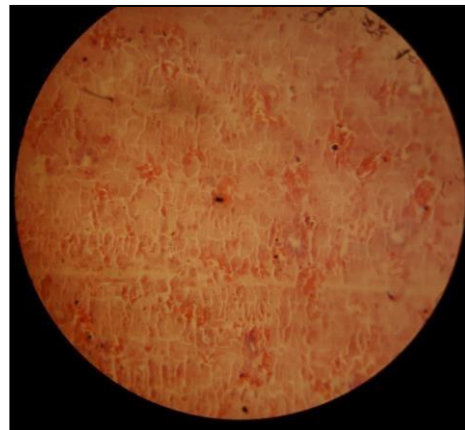
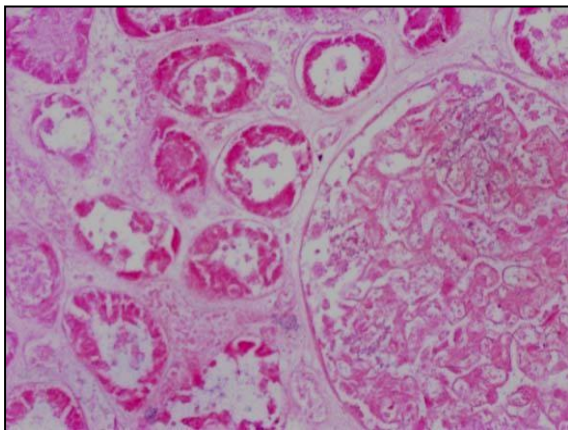


Diagnosis: Coagulative necrosis.

Organ: kidney.

Lesion:

1. Loss of cellular details of tissue and the outline of the tissue is remained.
2. Pyknosis of nuclei of epithelial cells lining the renal tubules in addition to karyorrhexis & karyolysis.
3. Cytoplasm of these cells become granular and eosinophilic

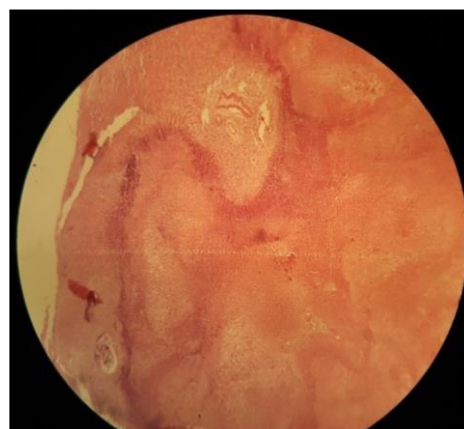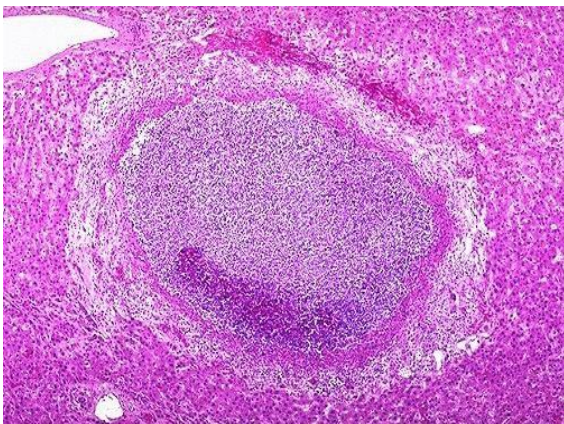


Diagnosis: Liquefactive necrosis.

Organ: liver.

Lesion:

1. Disappearance of architectural & cellular details of tissue.
2. Presence of many necrotic foci surrounded by cellular debris.
3. There is pink liquid material & it is represented the pus.
4. The necrotic area is surrounded by inflammatory cells represented by the live & dead neutrophils (line of demarcation).



Diagnosis: Caseous necrosis.

Organ: Lymph node.

Lesion:

1. Loss of cellular & architectural details of tissue.
2. Presence of homogenous pink material in the outer of necrotic area surrounded by phagocytes, plasma cells, lymphocytes, epithelioid cells & langhans giant cells.
3. Blue patches in the center of necrotic tissue which represent calcium salt deposition.

