

Anatomy

OSTEOLOGY

By: *DR. AMMAR ISMAIL*

Axial Skeleton

- **Thorax:** The boney cavity formed by the sternum, the ribs, the costal cartilage and the bodies of the thoracic vertebrae. The thorax encloses and protects the thoracic organs.
- **Ribs or Costa:**
 - Are elongated curved bone which form the skeleton of the lateral thoracic walls.
 - Each rib articulate with two adjacent thoracic vertebra and continued ventrally by the costal cartilage, which may be or may be not attached directly to the sternum.

Table: Showing the number of vertebrae in domestic animals, Total No. of ribs

Animals	Total No. of ribs	Sternal ribs	A sternal ribs	Floating ribs
Horse	18-19 pair	8 Pair	10 Pair	1 Pair
Cow	13	8 Pair	5 Pair	
Sheep	13	8 Pair	5 Pair	
Dog	13	9 Pair	4 Pair	
Cat	13	9 Pair	4 Pair	

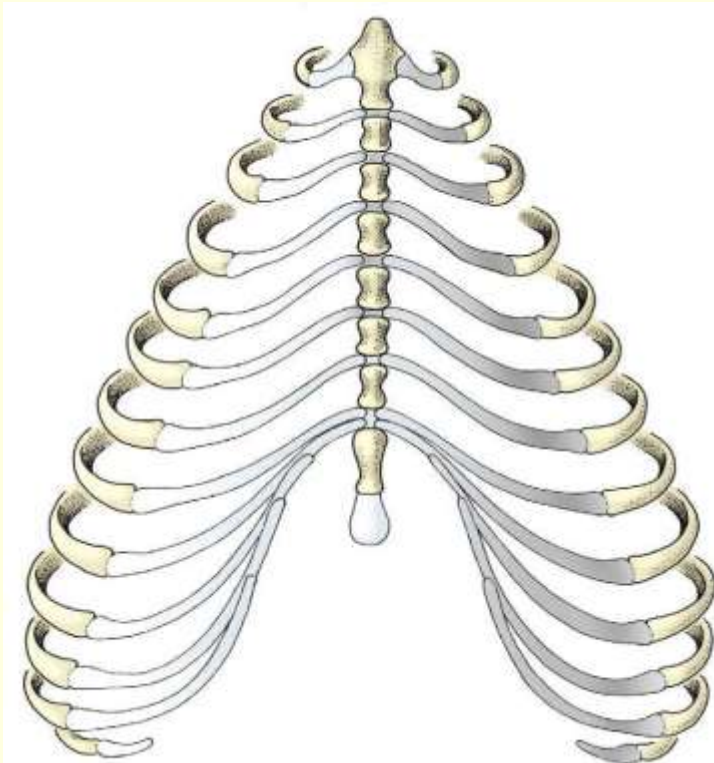
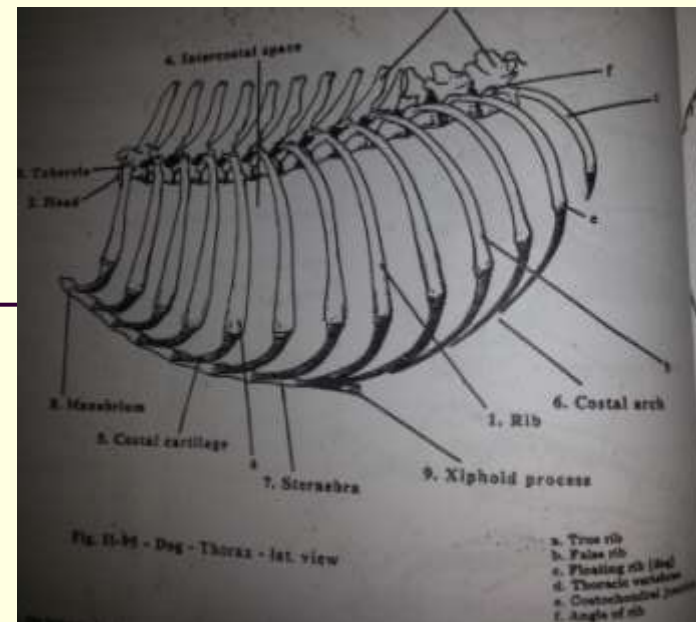
-
- Costal arch: Hyaline cartilage of false ribs which contact this rib directly or indirectly with the sternum.
 - This hyaline cartilage which act of overlap to form the costal cartilage

Ribs

True ribs: (sternal ribs) articulate by their costal cartilage with the sternum.(19)

False ribs: (asternal ribs): their costal cartilages unite to form the costal arch, indirectly joining them to the sternum.(20)

Floating ribs: found in the dog and man, end in the costal cartilages that do not join to the sternum or other costal cartilage(23)



Rib

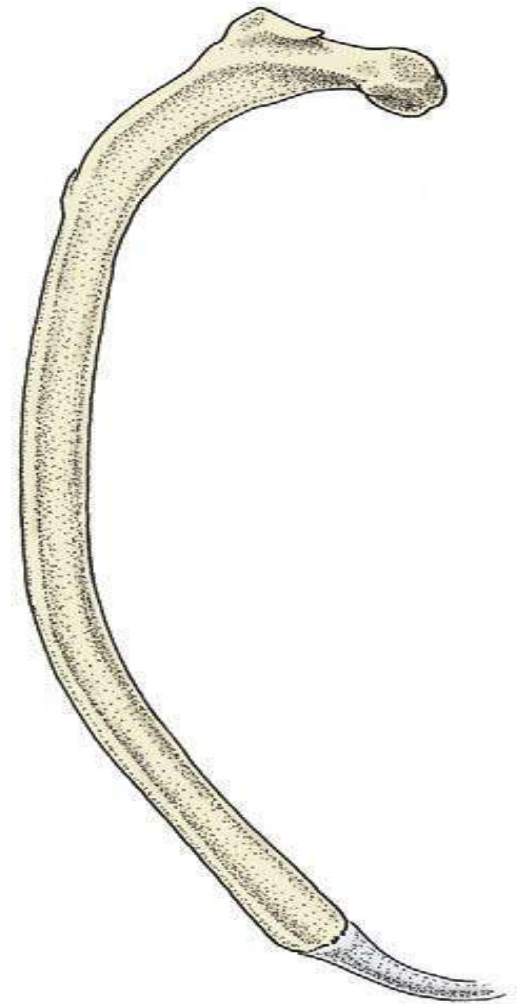
Morphologically the ribs consist of body and two extremities :

The dorsal extremity (vertebral extremity)formed from head and tubercle of rib .

Head of the rib : articulates with caudal and cranial costal facets of adjacent thoracic vertebrae and the intervening inter vertebral disc .

Tubercle of rib : articulate with the articular facet on the transverse process of same numbered vertebra .

The ventral extremity (sterna extremity) include costal cartilage .



Sternum: Brest bone

- The unpaired bones sternebrae forming the floor of the thorax.
- Manubrium: the expanded first sternebra
- Xiphoid process: the last sternebra which is a thin, horizontal bone capped by the xiphoid cartilage.
- **Number of sternebrae**
- carnivores: 8
- pig, horse and man : 6
- Ruminant :7