

Histopathological effect of ovine dermatophytosis show that the affected area of the skin before treatment by ivermectin which reflects three tissue changes, the first is hyper keratinization of the epidermis, the second is the presence of few inflammatory cells resemble by neutrophils and monocytes and the third is few fibrous connective tissue. Whereas, the affected area of the skin after treatment by ivermectin which reflects four tissue changes; the first is incomplete healing of the epidermis; the second is the presence of high number of inflammatory cells resemble by eosinophils, monocytes and neutrophils; the third is too much fibrous connective tissue and prevascular cuffing cells as in figure (4 a-b).

Table 1: Frequency distribution of ovine dermatophytosis according to months of study

Months	No. of Examined samples	No.(%) of Positive samples
November 2013	6	4(66.66%)
December 2014	6	4(66.66%)
January 2014	8	6(75%)
February 2014	8	7(87.5%)
March 2014	8	8(100%)
April 2014	8	6(75%)
May 2014	6	5(83.33%)
Total	50	40(80%)

$X^2 = 3.906$; $P < 0.05$, N.S.D

$X^2 =$ Chi-Square, NSD = No Significant difference

Table 2: Frequency distribution of sheep with ovine dermatophytosis lesions according to age

Age	No. of Examined samples	No.(%) of Positive samples
2-12 month	30	27 (90%)
2-5 years	20	13 (65%)
Total	50	40 (80%)

$X^2 = 4.688$, $P < 0.05$, S.D.

$X^2 =$ Chi-Square, SD = Significant difference

Table 3: Type of treatment and the time of clearance of ovine dermatophytosis lesions

Animal groups	treatment Dosage	Period of clearance
Ivermectin treatment	1 % Ivermectin	13-24 Days*
Iodine treatment	2 % Iodine ointment	30-40 Days

Table 4: Heamatological change of sheep with ovine dermatophytosis treated by ivermectin

The parameters	Normal range	Before treatment M± S.D	After 11 days of treatment M± S.D
Pocked cell volume (PCV) (%)	24-45	23 ± 2.68	22 ± 1.26
Hemoglobin (Hb) (g/dL)	8-15	7.6± 0.087	7.4± 0.196
Platelets (Per/ µL)	250000 - 750000	795000 ± 1.34	865000± 1.46
Red blood cell (RBC) (x10 ⁶ / µL)	9.0-15.0	8,755,250± 1.22	7,883,350± 1.32
Mean corpuscular volume (MCV) (fl)	28-40	26± 1.41	27±0.632
Mean corpuscular hemoglobin (MCH) (Pg)	8.0-12.0	8 ± 1.264	9 ± 1.032
Mean corpuscular hemoglobin concentration (MCHC) (g/L)	31.0-34.0	33± 0.632	33.6 ± 0.752
White blood cell count (WBC) (Per/ µL)	4000-12.000	5125± 0.418	5.138 ± 0.422
Neutrophils %	20-42	43± 0.894	45 ± 1.560
Lymphocytes%	40-75	39± 1.366	24 ± 0.830*
Monocytes %	0-6	8± 1.264	10 ± 0.152*
Eosinophils %	0-10	9± 0.632	20 ± 1.092*
Basophils %	0-3	1 ± 0.582	1± 0.582

M= Mean, SD= Stander division, Significant difference ($P < 0.05$)

Table 5: Evaluation of different concentrations of ivermectin in *T. mentagrophytes* as growth in vitro

No.	Concentrations	T- test value (1,2)	T- test value (1,3)	T- test value (2,3)
1	0.001%	26.77*	87.42*	40.0*
2	0.02%			
3	0.04%			

*significant difference at ($P < 0.05$)




Figure 1: Reveals the efficacy of ivermectin in treatment of ovine dermatophytosis and show the clearance of the lesions in the lambs with hair regrown. A: before treatment, B: After treatment



Figure 2: A: The shape of completely grow colony of *T. verrucosum* fungi on (SDA) at 37C°. B: The shape of completely grow colony of *T. mentagrophytes* fungi in (SDA) at 37C°



Figure 3: Shows the inhibitory effect of three concentrations of ivermectin on *T. mentagrophytes* as growth *in vitro*.
Plate No.1, the concentration mean = 0.001%
Plate No.2, the concentration mean= 0.02%
Plate No.4, the concentration mean= 0.04%.

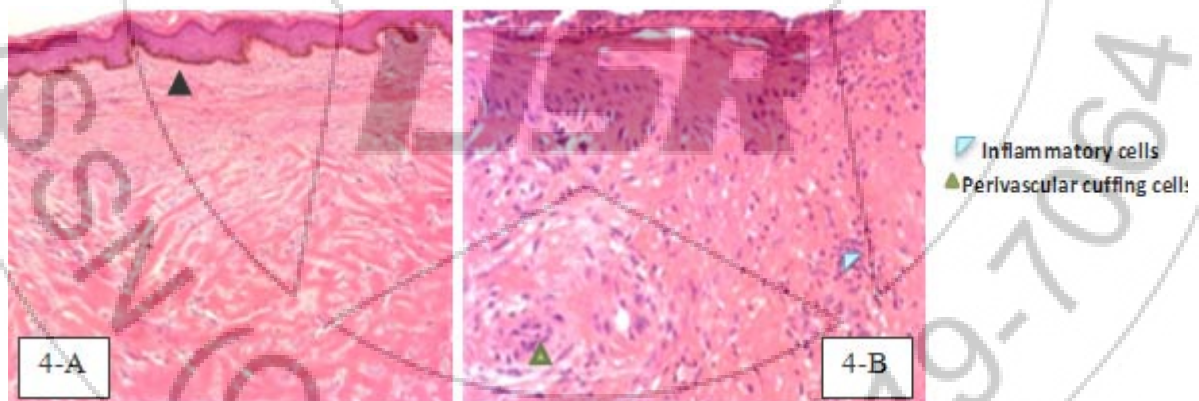


Figure 4(a): Revealed the histopathological section of affected area of the skin before treatment by ivermectin. (20 X).
Figure 4(b): Revealed the histopathological section of affected area of the skin after treatment by ivermectin.(40X)

4. Discussion

The high percentage of ovine dermatophytosis 80% may indicate endemic nature, environmental conditions, overcrowding and continuous exposure to the causative agent which agree with opinion of others [19, 20]. Higher percentage of infection in young sheep than adult sheep may attributed to animals age, sucking of lamb from infected ewes. This opinion comes in concordance with [3], they reported the age and trauma are important predisposing factors of disease and the infection mainly occurs in lambs and is rapidly spread in the herd via infected propagates.

After culture and examination, *T. verrucosum* represent the majority of isolates characterized by chlamydo spores in chain; rare macroconidia. *T. mentagrophytes* represents the minor isolates that reveals the presence of chlamydo spores, microconidia and macroconidia. These results make us to say, the *T. verrucosum* is the usual cause of ringworm in sheep that agree with [21] who proved that *T. verrucosum* isolated from 70% of ram lambs. *T. mentagrophytes* and *T. verrucosum* equally cause ringworm infection of sheep [19].

In the present study we used the injectable ivermectin as biological source of treatment more benefit and less side

effect, and better than chemical drugs which are used locally. [22] elicits the side effects of some topical antifungal drugs as amphotericin B and ketoconazole and miconazole which cause anorexia, vomiting, seizures, and cardiac arrest, which have been reported with the use of amphotericin B. Ketoconazole may produce hepatotoxicity. Miconazole may produce tachycardia, arrhythmias, fever, nausea, and thrombophlebitis after intravenous administration. [13] were ensures that mammals can ingest ivermectin with a high degree of safety.

Significant difference ($p < 0.05$) was recorded in duration of treatment (13-24 days) with ivermectin compared with topical antifungal such as iodine compound which needs more time for clearance between 30-40 days and needs high cost [17]

The hematological changes of ivermectin in blood parameter show significant elevation ($P < 0.05$) in the rate of eosinophils and monocytes in addition to activation of the neutrophils after treatment by ivermectin which may attributed to the effect of ivermectin on stimulation of cellular immune response of the animal. This explanation come in concordance with [23]. They recorded these cytotoxic materials which released by stimulated eosinophils may be cause damage in the cell membrane of the fungus and facilitate the drug entrance inside the target cells with its cytotoxic effect [24], mentioned that eosinophil granules cationic proteins induce tissue damage and dysfunction. [25] had been proved the ability of dendritic cells to phagocytose or engulf the two proliferative forms of *Aspergillus fumigatus* the conidia and hyphae.

This study agree with [26] which refer to immunopotentiating effect of ivermectin on treated animals when the dose was duplicated because, the potent cause which interfere with disease cure is the good immunity. Other studies were refers to the role of cellular branch of immune system in protective immunity against dermatophyte infections [27, 28]. The idea is supported by other study which reflect the ability of the ivermectin at a dose 300 mg /Kg. B.W to enhance antibody production and lymphocytes number results in treatment the early formed bovine warts not in advance stages [29]. This result didn't has any side effects on the animals health along the period of treatment because the ivermectin is nationally used in treatment of the endo and ectoparasites in ruminants. This study was agree with [15] which proved the ability of ivermectin in treatment of ringworm infection in cattle. This study disagree with [30] mentioned that ivermectin have no antibacterial or antifungal activities although it is structurally similar to macrolide antibiotics and antifungal macrocyclic polyenes. This structural similarity of macrolides may leads to this effect on the causative agent. Our study was supported by *in vitro* experiment that revealed the effect of inoculated ivermectin to *Trichophyton mentagrophytes* fungus culture. These findings proved that ivermectin could be used successfully and effectively in the treatment of ovine dermatophytosis, minimizing the duration and the cost of treatment in addition to other uses in treatment of mange, skin lice and some endoparasites.

References

- [1] Singh G, Kumar P, Joshi SC: Treatment of dermatophytosis by a new antifungal agent apigenin™. *Mycoses* 2014.
- [2] Quinn PJ, Markey BK, Leonard FC, Fitz-Patrick ES, Fanning S, Hartigan PJ: *Dermatophytosis in Cattle. Veterinary Microbiology and Microbial Disease.*, second edition edn; 2011.
- [3] Oborilova E, Rybnikar A: Experimental dermatophytosis in calves caused by *Trichophyton verrucosum* culture. *Mycoses* 2005(48):187-191.
- [4] Al-Saidy HAM, Jameel GH, Sultan AA: Evaluation of *Calvatia Craniformis* Mushroom Activity in Treatment of Ringworm Disease Ion Cattle. *Journal of Biology, Agriculture and Healthcare* 2014, 4(19):1-5.
- [5] Anupama A: Isolation, Identification And Antifungal Susceptibility Of Dermatophytes From Clinical Samples – One Year Study. KLE University, Belgaum, Karnataka; 2014.
- [6] Brioudes AI, Warner J, Hedlefs R, Gummow B: A review of domestic animal diseases within the Pacific Islands region. *Acta tropica* 2014, 132:23-38.
- [7] Taylor C, Gurr S: Fungal pathogenesis: Past, present and future. *Fungal Biology Reviews* 2014, 28(1):24-28.
- [8] Agnetti F, Righi C, Scoccia E, Felici A, Crotti S, Moretta I, Moretti A, Maresca C, Troiani L, Papini M: *Trichophyton verrucosum* infection in cattle farms of Umbria (Central Italy) and transmission to humans. *Mycoses* 2014.
- [9] Akbarmehr J: The prevalence of cattle ringworm in native dairy farms of Sarab city (East Azarbayjan province), Iran. *African Journal of Microbiology Research* 2011, 5(11):1268-1271.
- [10] EL-DIASTY EM, AHMED M, OKASHA N, MANSOUR SF, EL-DEK SI, EL-KHALEK HMA, YOUSSEF MH: ANTIFUNGAL ACTIVITY OF ZINC OXIDE NANOPARTICLES AGAINST DERMATOPHYTIC LESIONS OF CATTLE. *Rom J Biopsy* 2013, 23(3):191-202.
- [11] Ghodasara S, Murthy K, Gajbhiye P, Savalia K, Ahlawat A: Comparative Evaluation of Chemotherapeutics for Ringworm Management in Gir calves. *Intas Polivet* 2013, 14(2):336-339.
- [12] Quinn PJ, Markey BK, Leonard FC, Hartigan P, Fanning Sa, FitzPatrick E: *Veterinary microbiology and microbial disease: John Wiley & Sons; 2013.*
- [13] Omura S: Ivermectin: 25 years and still going strong. *International journal of antimicrobial agents* 2008, 31(2):91-98.
- [14] Cheesbrough M: *District laboratory practice in tropical countries: Cambridge university press; 2006.*
- [15] KIRMIZIGÜL AH, GÖKÇE E, ŞAHİN M, Kiziltepe Ş, BÜYÜK F, ERKILIÇ EE: Clinical Effectiveness of Ivermectin on Bovine Dermatophytosis. *Kafkas Univ Vet Fak Derg* 2012, 18(3):523-526.
- [16] Bogan JA, Mckellar QA: The pharmacodynamics of Ivermectin in sheep and cattle. *Br J Pharmacol* 2001, 132(6):1247 - 1254.
- [17] Radostits GM, Gay CC, Blood DC, Hinchcliff KW: *Veterinary medicine. A textbook of the disease of cat-*

- tle, sheep, pigs, goat and horses., ninth edition edn; 2000.
- [18] J.H. Z: Biostatistical analysis, second edition edn: prentice Hall Inc., Englewood, N.J.s. ; 1984.
- [19] Gupta AK, Cooper EA: Update in antifungal therapy dermatophytosis. *Mycopathologia* 2008, 166(5): 353-367.
- [20] Webber R: Communicable disease epidemiology and control: A global perspective: Cabi; 2009.
- [21] Sargison N: ringworm in sheep. In.; 2014.
- [22] Wanamaker BP, Massey KL: Polyene Antifungal Agents. *Applied Pharmacology for the Veterinary Technician*, third edition edn: Saunders.; 2004.
- [23] Gleich G, Adolphson C: The eosinophilic leukocyte: structure and function. *Adv Immunol* 1986, 39:177-253. .
- [24] Young J, Peterson C, Venge P., Cohn Z . Mechanism of membrane damage mediated by human eosinophil cationic protein. *Nature* 1986, 321 (6070): 613-616. .
- [25] Bozza S, Gaziano R, Sperca A, Bscei A, Montagnoli C, Francesco P, Roman L: Dendritic cells transport conidia and hyphae of *Aspergillus fumigatus* from the airways to the draining lymph nodes and initiate disparate Th response to the fungus. . *J Immunol* 2002, 168:1362 -1371.
- [26] Sajid MS, Iqbal Z, Muhammad G, Sandhu MA, Khan MN, Saqib M, Iqbal MU: Effect of ivermectin on the cellular and humoral immune responses of rabbits. *Life sciences* 2007, 80(21):1966-1970.
- [27] Kaaman T: Current Topics in Medical Mycology., vol. 1. New York: Springer-Verlag.; 1985.
- [28] Sohnle PG. In: *Fungal infections and Immune Response*. New York, Plenum; 1993: 27 -47.
- [29] Ghassan H J, Saba J J, Thekra A E, Wasan A M: Study of Ivermectin effect on the bovine warts Diyala journal for pure sciences 2011, 7 (2):117-126.
- [30] Taylor HR, Greene BM: The status of ivermectin in the treatment of human onchocerciasis. *Am J Trop Med Hyg* 1989, 41:460-466.

Author Profile

Ghassan H. Jameel, Assistant Professor, Department of Microbiology, College of Veterinary Medicine,, University of Diyala, Iraq.

Tareq R. Minnat, Assistant Lecturer, Department of internal and preventive medicine, College of Veterinary Medicine, University of Diyala, Iraq.

Anas A. Humadi, Assistant Lecturer, Department of pathology, College of Veterinary Medicine University of Diyala, Iraq.

Ali Ibrahim Ali Al-Ezzy, Assistant Professor, Department of pathology, College of Veterinary Medicine, University of Diyala, Iraq.