

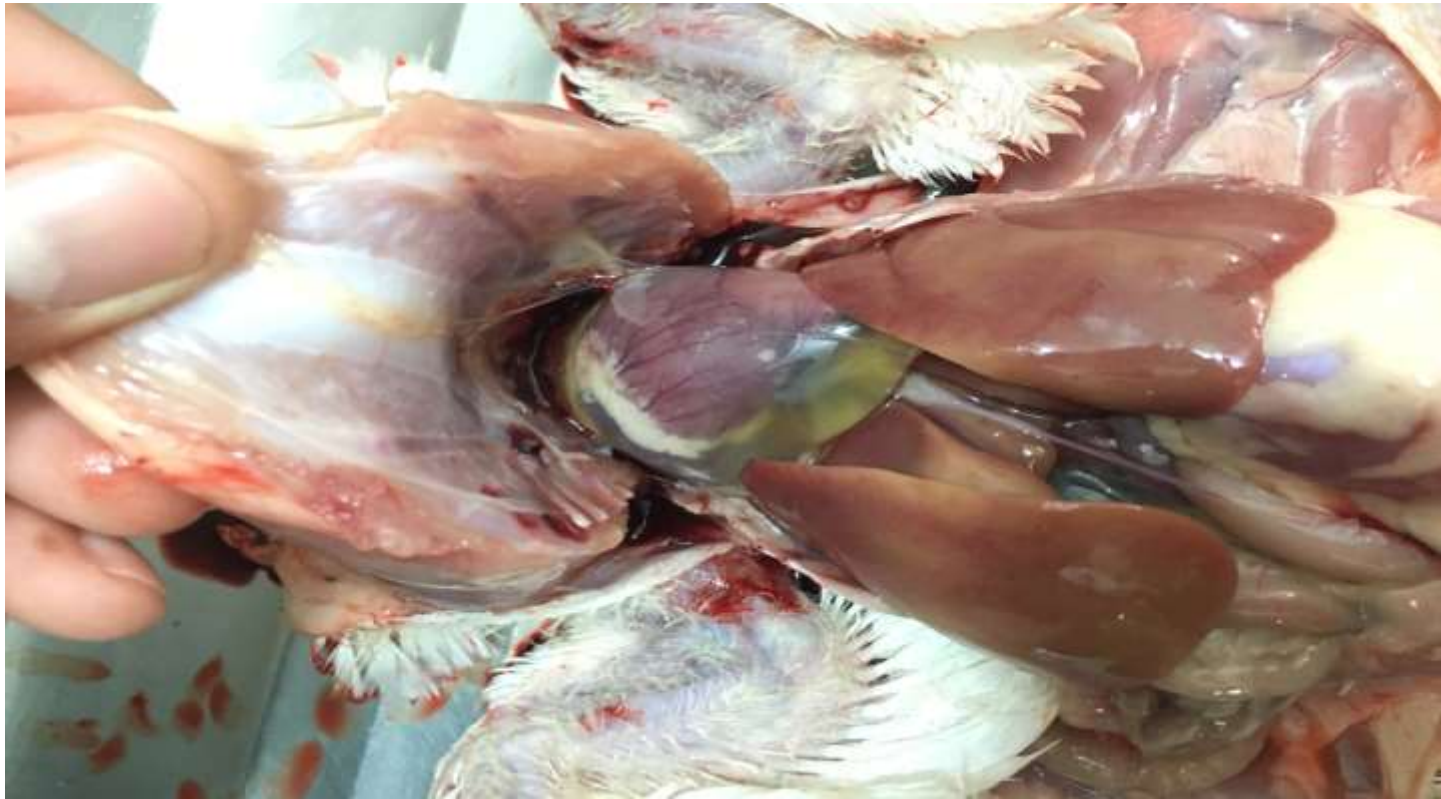IBH, HHS

**Inclusion Body Hepatitis
hydropericardium hepatitis
syndrome, or Adenovirus
infection in chickens.**



**Asistance Prof
Amer Alazawy**

Adenoviruses are widespread throughout all avian species. Studies have demonstrated the presence of antibodies in healthy poultry, and viruses have been isolated from normal birds.



The term adeno comes from the Greek word (aden) meaning gland. The first AAV associated with clinical disease was isolated from an outbreak of respiratory disease in **quail** in 1950 . Since that time, AAVs have been found to be ubiquitous in all types and breeds of chickens (normal flora). Natural outbreaks are characterized by a sudden onset of sharply increased flocks mortality (up to 30%). **The disease was first described in the U.S. in 1963** and since then has been reported in **many countries** around the world including **Iraq during 1997**. Subsequently, it was determined to be associated with avian adenovirus (AAV) infection.

The first avian adenovirus (AAV) was isolated from chicken embryos which had been inoculated with calf tissue during studies on the etiology of **LSD**.

To date, 19 avian serotypes plus the virus of egg drop syndrome (EDS) and turkey hemorrhagic enteritis (THE) related viruses were known.

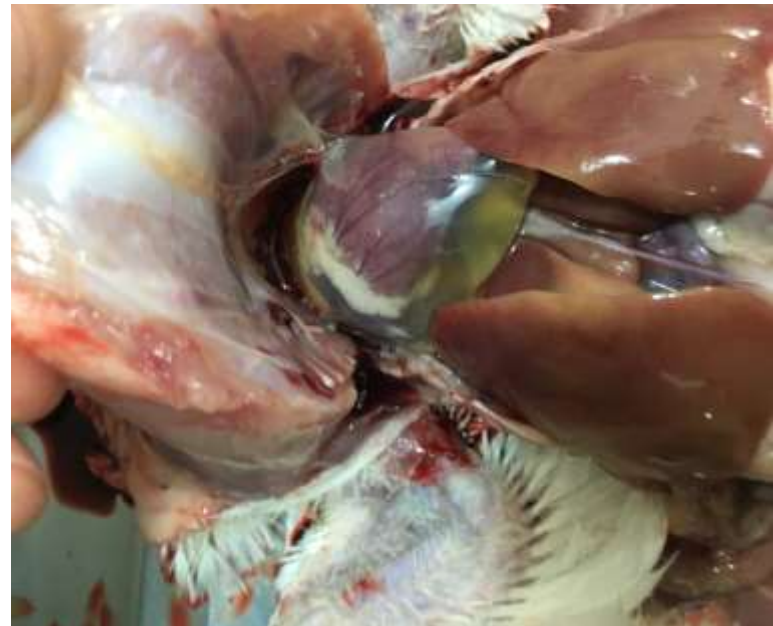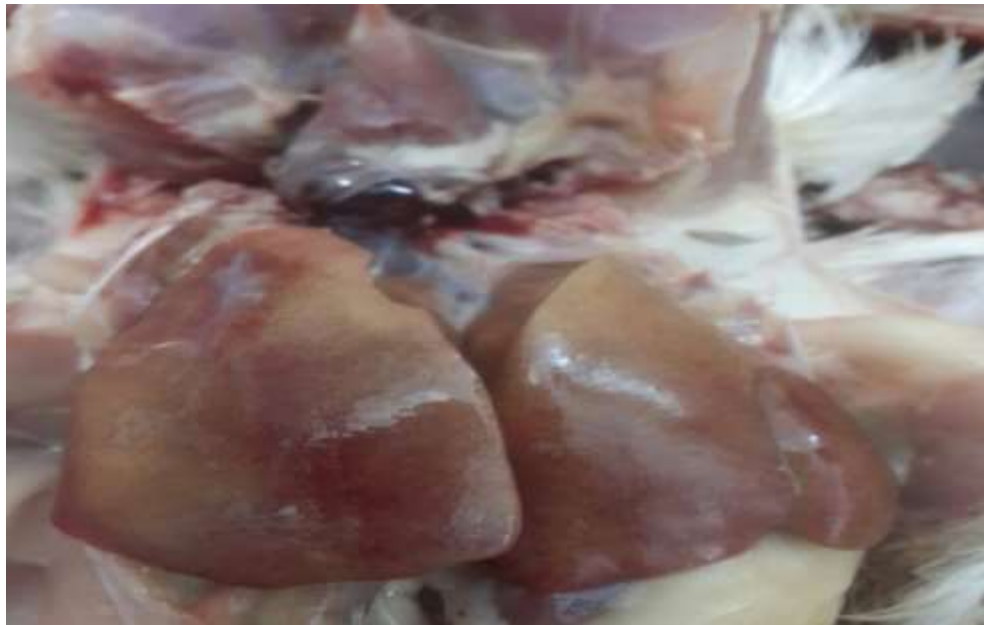Despite their widespread distribution, most adenoviruses cause no or only mild disease; however, some are associated with specific clinical conditions.

Avian adenoviruses (AAVs) in chickens are the etiologic agents of two important diseases known as **inclusion body hepatitis (IBH) and hydropericardium hepatitis syndrome (HHS)**.

Although in some cases each disease is observed separately, the two conditions have been frequently observed as a single entity; therefore, the name hepatitis hydropericardium has been widely used to describe the pathologic condition.

The syndrome is an acute disease of young chickens associated with anemia, hemorrhagic disorders, and hydropericardium. It is a common disease in several countries, where broilers are severely affected, resulting in high mortality rates.

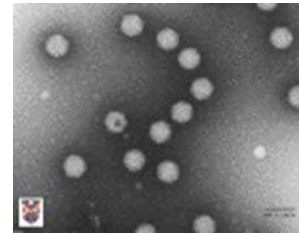
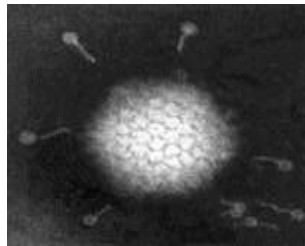
Inclusion body hepatitis (IBH) is an acute viral disease caused by avian adenovirus with highly pathogenic strain lead to heavy mortality and unusual lesion like hydropericardium in commercial broilers (meat-type chickens under six weeks of age but can occur as early as six days and as late as 20 weeks). The causative agent of this form of the disease is any of several serotypes of **group I AAV**.



Etiology

The family Adenovirus comprises a large number of serotypes both of **human and animal origin** including those of birds.

Adenoviruses is a members of the family **Adenoviridae**. By **Electron microscopic** studies of several adenoviruses from human and animal sources indicate that the virus is **DNA** virus of medium-sized, icosahedral shape with a diameter of (80-90 nm). The virion has no envelope and possesses a core of 60-65 nm. The virion consists of two structural complexes: the capsid (outer icosahedral shell) and the core (internal body comprising the nucleocapsid and the core shell). The nucleocapsid consists of DNA and 3-4 closely associated proteins. The **icosahedral** capsid is composed of 252 hollow capsomeres.



The family Adenoviridae is subdivided into two genera:

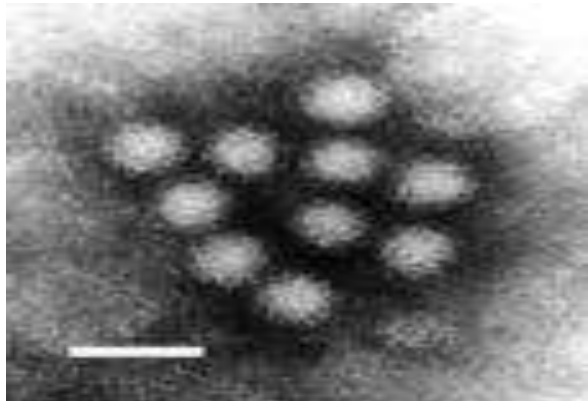
1-Mastadenovirus representing all mammalian adenovirus.

2-Aviadenovirus (AAVs).

On the basis of the type-specific antigens:

The genus Mastadenovirus: Is a genus of viruses in the family Adenoviridae. Human, mammals, and vertebrates serve as **NATURAL hosts**, comprising, 41 human, 24 nonhuman primate, 9 bovine, 4 porcine, **5 ovine**, 2 equine, 2 canine, 1 caprine, 2 murine serotypes.

Diseases associated with this genus include: very common human infection, estimated to be responsible for between 2% and 5% of all respiratory infections.

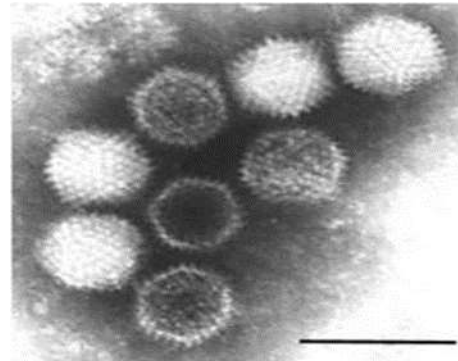


Adenoviruses isolated from **different avian species** are divided into three groups designated **I, II and III** on the basis of their subgroup-specific antigens.

Group I :Represents the conventional **19 serotypes(1-19)** isolated from **fowl, turkey, goose, pheasant, duck** and other avian species.

Group 11: Represents viruses closely related to the, marble spleen disease of pheasants(MSD) and splenomegaly of chickens while the **group III** viruses closely related to EDS of chickens.

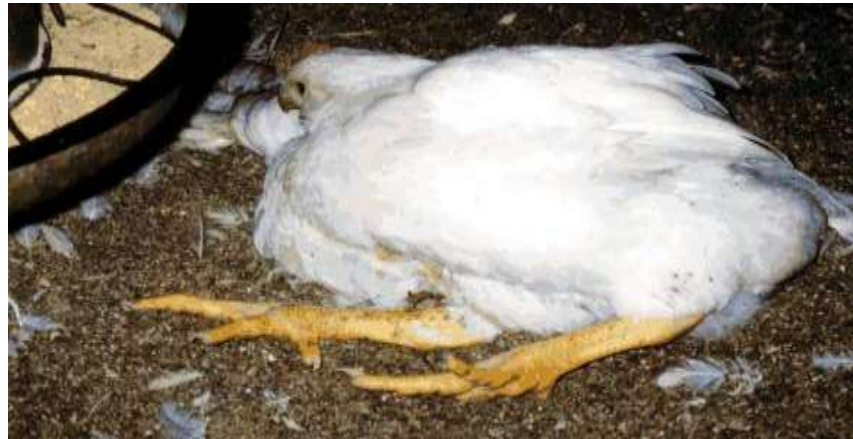It is likely that differences in virulence between viral strains may contribute to the variation in severity of the disease in addition to any environmental or host factor.



The most common viruses isolated in cases of IBH/HHS belong to **serotypes 4 and 8**. These AAVs are capable of producing the disease without the immunosuppressive effects of associated viruses such as infectious bursal disease (IBDV) or other immunosuppressive agents. However, the association with immunosuppressive viruses such as IBDV and chicken anemia virus (CAV) **will result in a more severe disease**.

Some AAVs are frequently isolated from apparently healthy birds and their etiological role in specific clinical diseases is often regarded as in significant. However, some AAV infections are associated with a variety of evident disease syndromes such as hepatitis, respiratory disease, drop in egg production, decline in egg shell quality, atrophy of the bursa and thymus, hemorrhages in muscles, splenomegaly.

An adenovirus will reproduce the disease in **immunosuppressed** birds. **Gumboro virus** plays a role in the field problem. Lack of maternal antibody will result in an early Gumboro infection which leads to immunosuppression. In recent years inclusion body hepatitis (IBH) has emerged as an economically important disease in **Iraq**. Historically, infections with infectious bursal disease virus (IBDV) and chicken anemia virus (CAV) have been known to suppress the immune system of broilers and make them more susceptible to a secondary disease such as **IBH or HHS**. Whereas, recently it has been reported that **virulent adenoviruses** are able to cause **IBH** as a primary disease in broilers without apparent involvement of **IBDV or CAV**.

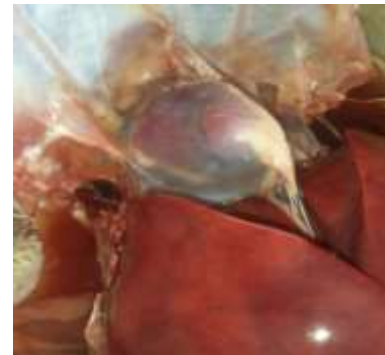


A hydropericardium syndrome(Angara Disease)(HHS):

This condition was first appeared in the commercial broiler chickens in Angara Goth near Karachi, **Pakistan during late 1987**, causing high mortality. Later the syndrome has also affected medium weight laying strains and broiler breeder strains of the chicken. The disease primarily affects liver, heart, kidneys and lungs. **It has been subsequently reported in Iraq during 1991s.** (Abdul-Aziz and Al-Attar 1991).

HHS caused by a fowl adenovirus (FAV) **group I, serotype 4.**

, possibly in combination with an RNA virus and immunosuppression caused by Chick **Anemia virus** or Infectious **Bursal Disease**. The disease is readily reproduced by inoculating birds with a bacteria-free filtrate of a liver extract from an affected bird. Mortality may reach 60% but more typically 10-30%.



Clinical signs :

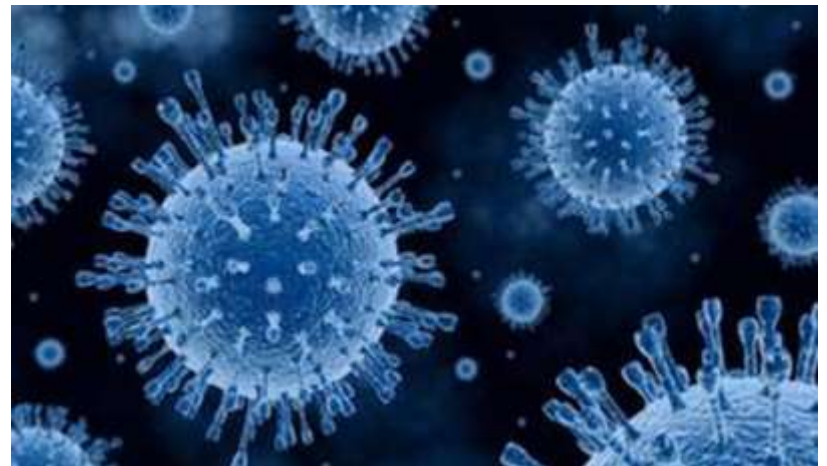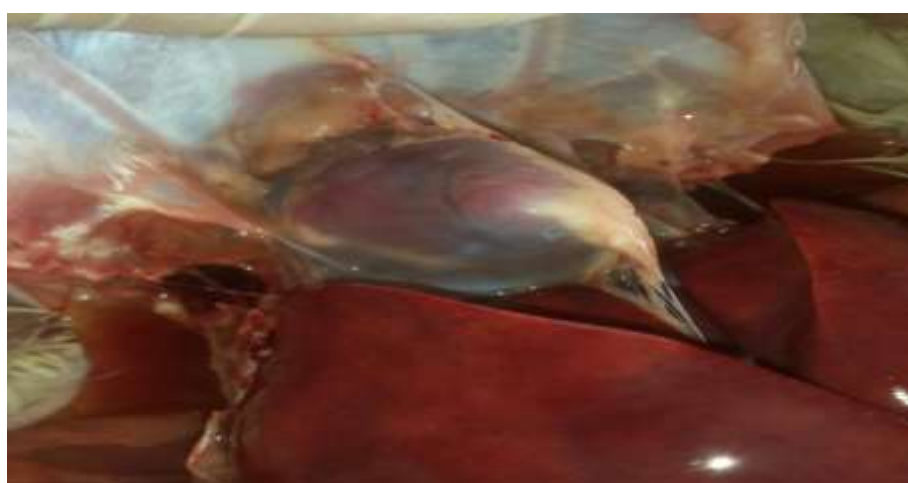Sudden onset and high mortality (up to 40% in well-grown, clinically healthy broiler flocks) usually is seen in chickens <6 weeks old and as young as 4 days of age.

Generally there are no apparent specific clinical signs associated with the disease. In outbreaks, there is a sudden onset of mortality that usually ranges from 2 -10%, but in some cases may be over 40%, and some individual birds occasionally are **depressed, huddle in corners and have ruffled feathers before death.** Paleness of comb and wattles, **Yellow, mucoïd droppings may be seen. The duration of the infection usually ranges from 9–14 days.**



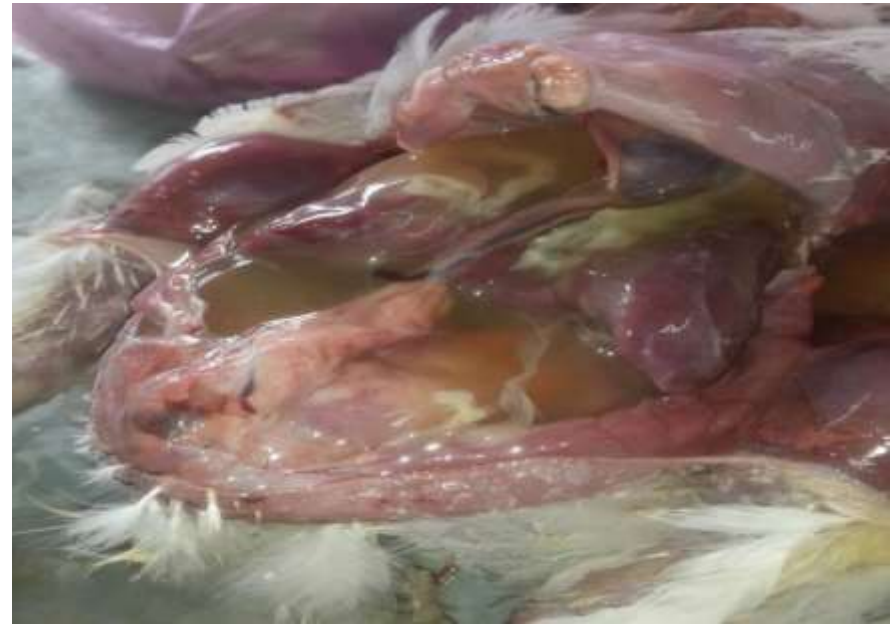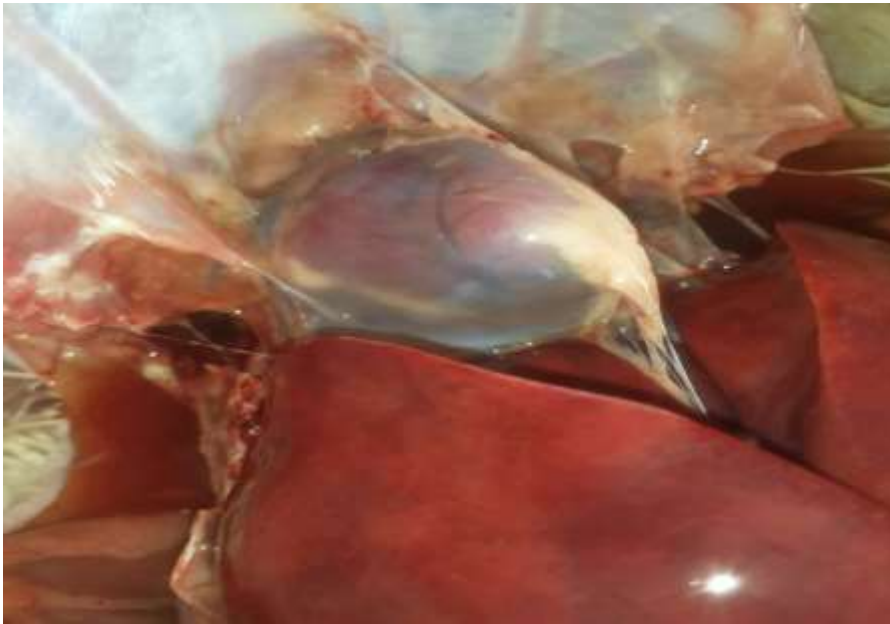
In some outbreaks of the virus, mortality has reached 60%. Mortality will vary depending on **the pathogenicity of the virus, susceptibility of the chicks (level of maternal immunity)** and secondary infections with other viral or bacterial agents. Signs associated with diseases caused by other pathogens (eg, bacteria, fungi, or viruses) commonly occur if birds are immunosuppressed

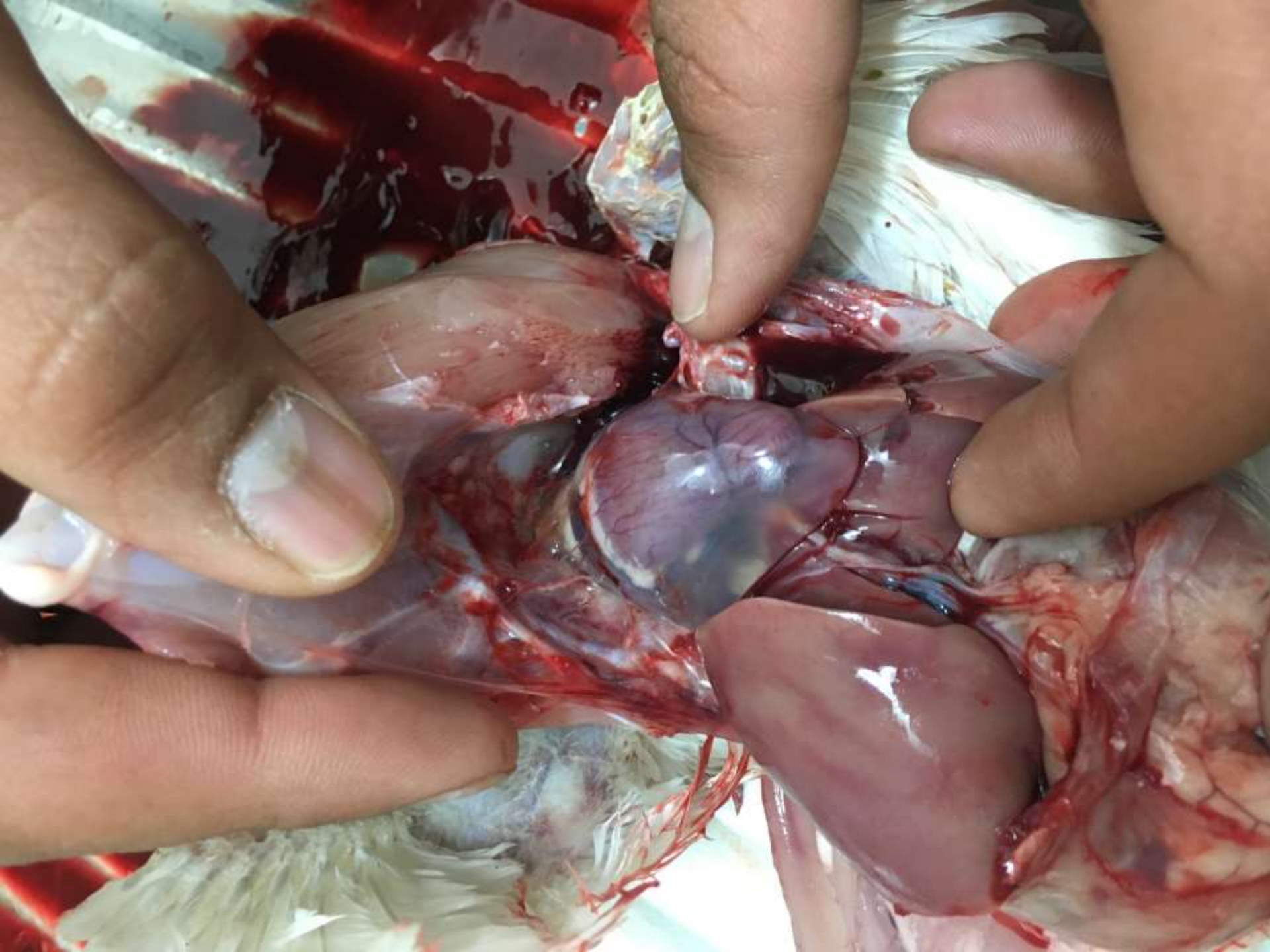
Mortality generally peaks **within three to four days and terminates within one week**, although in some cases it may remain for several weeks.

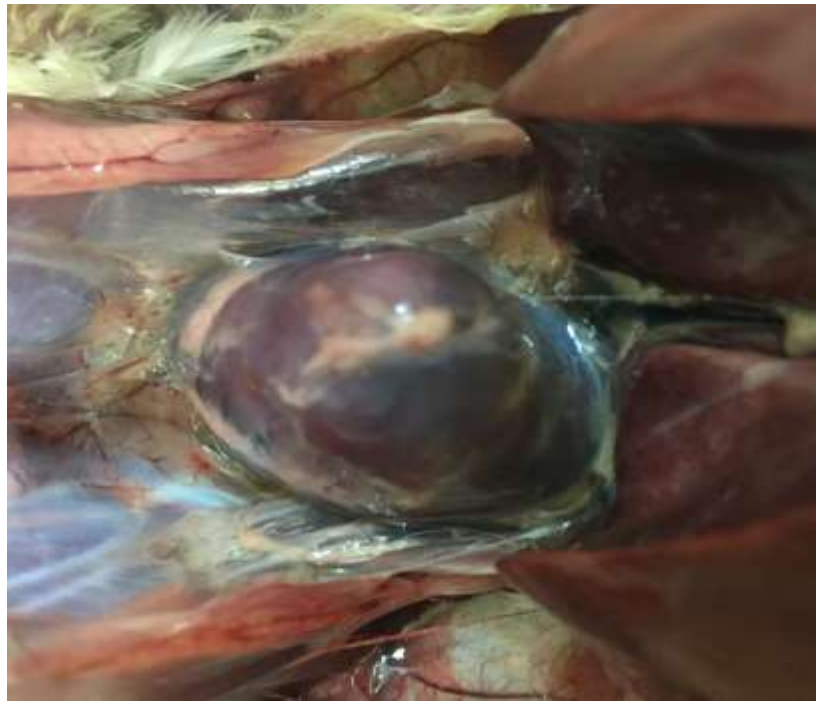
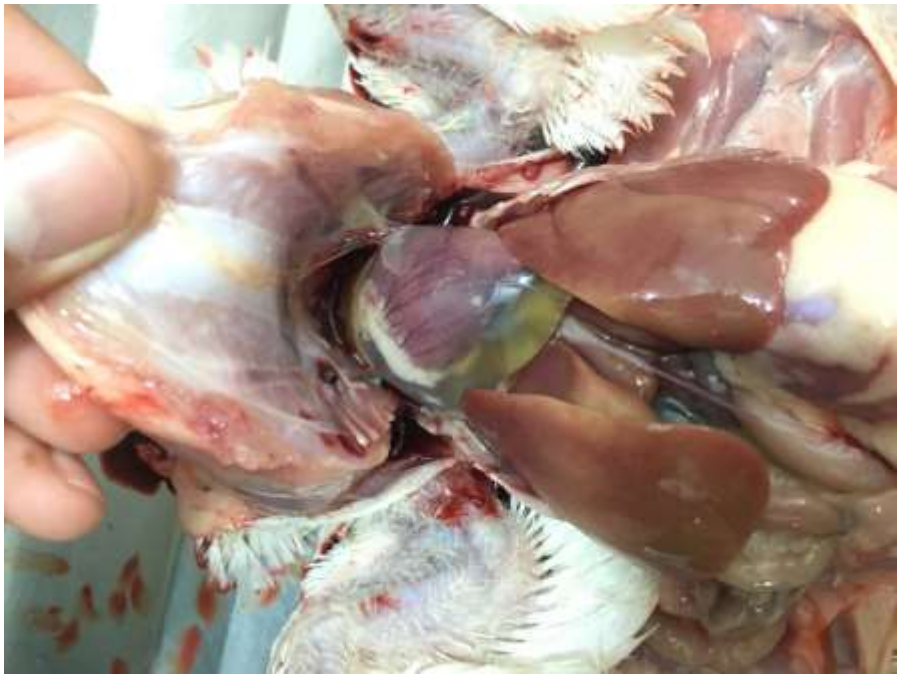

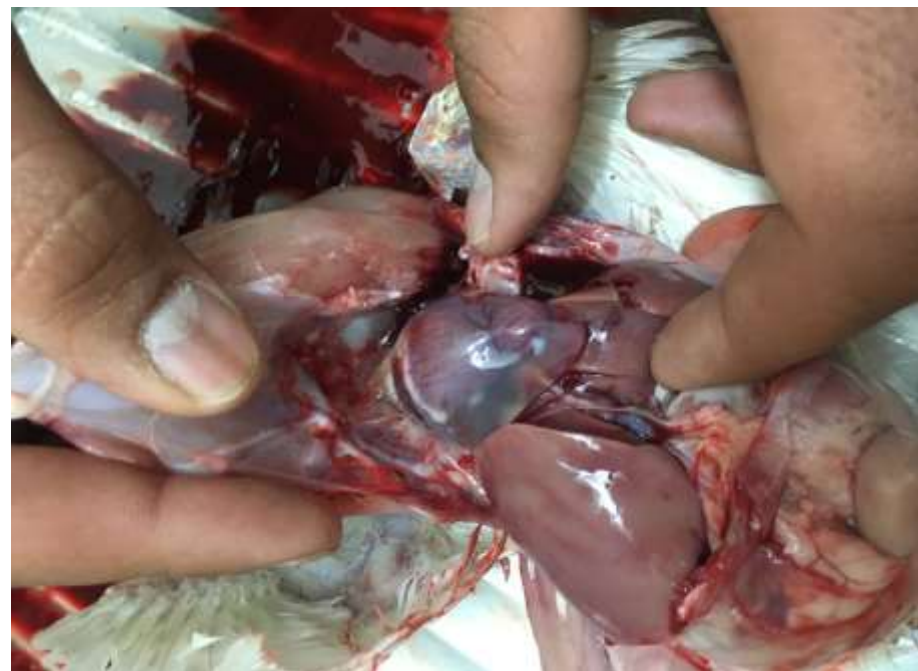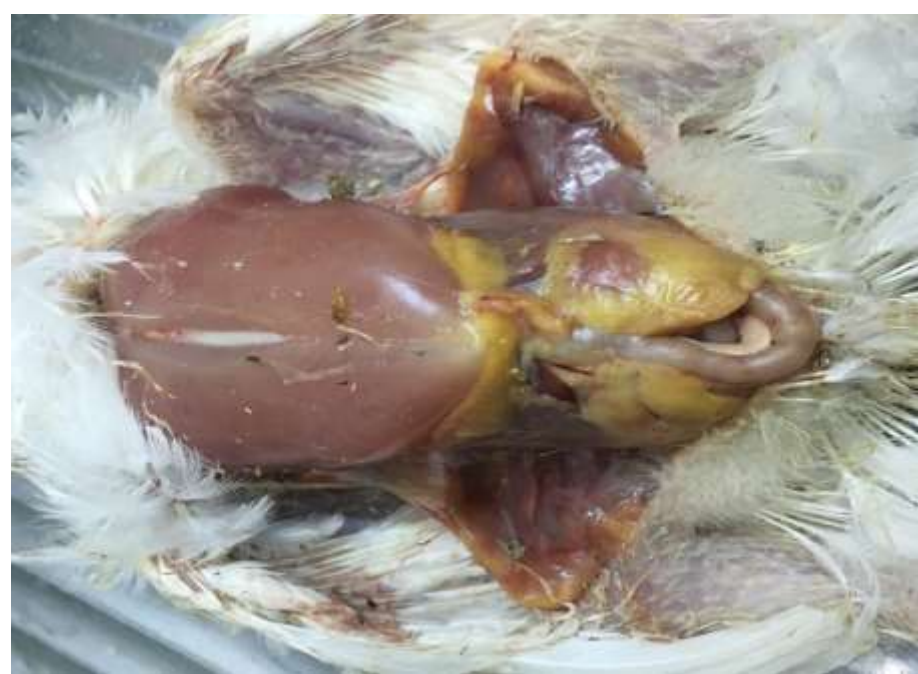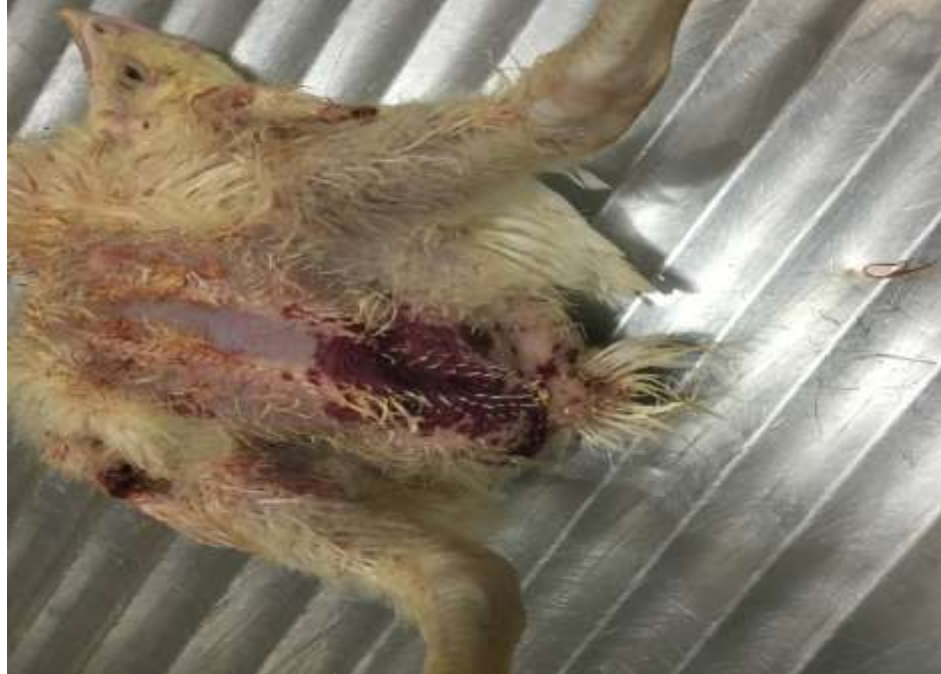Gross lesions:

include accumulation of clear, straw-colored, watery or jelly-like fluid in the pericardial sac with the quantity of fluid ranging from 5 to 20 ml and a misshapen and flabby heart.



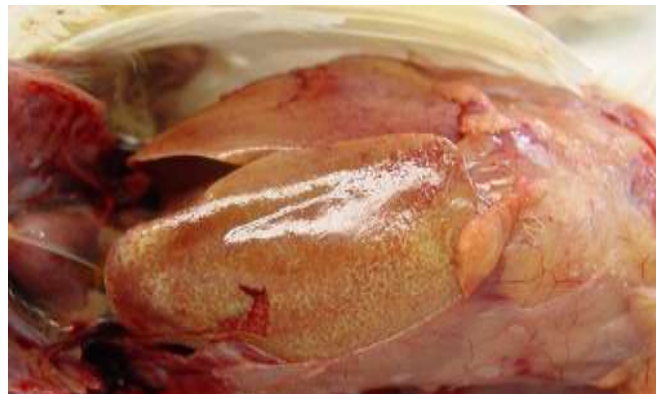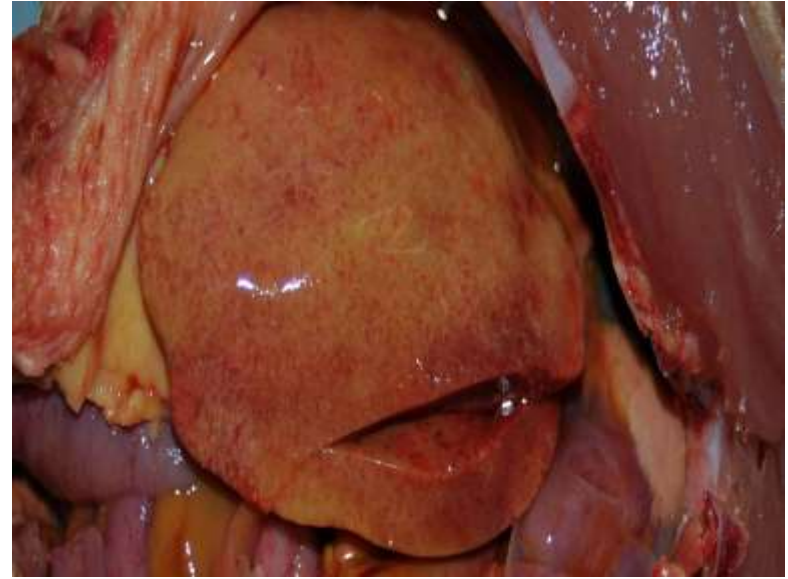

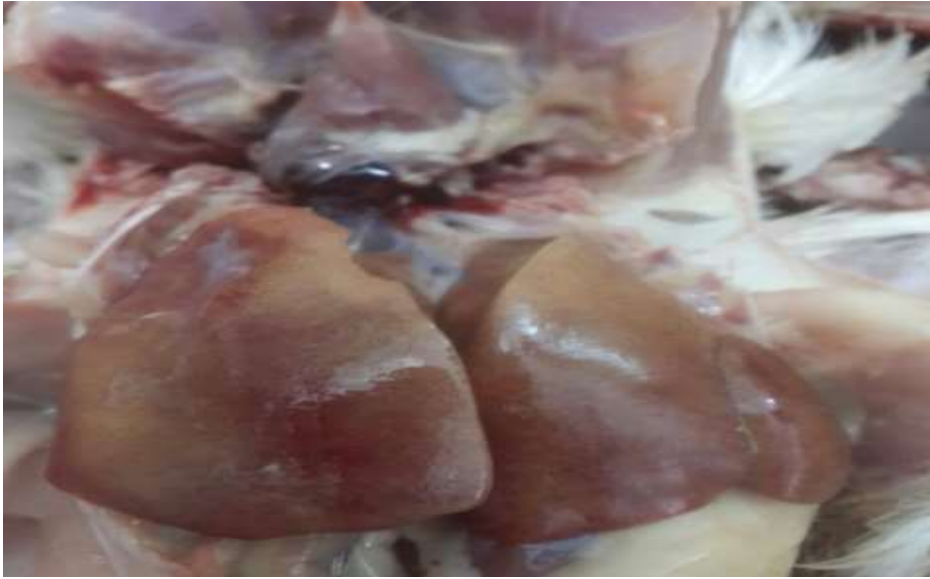




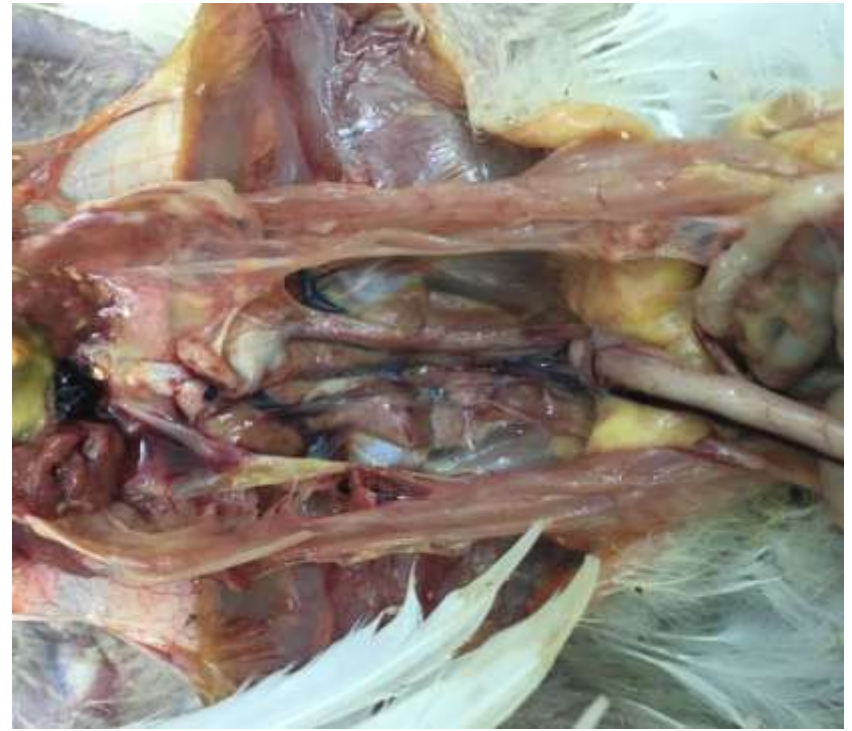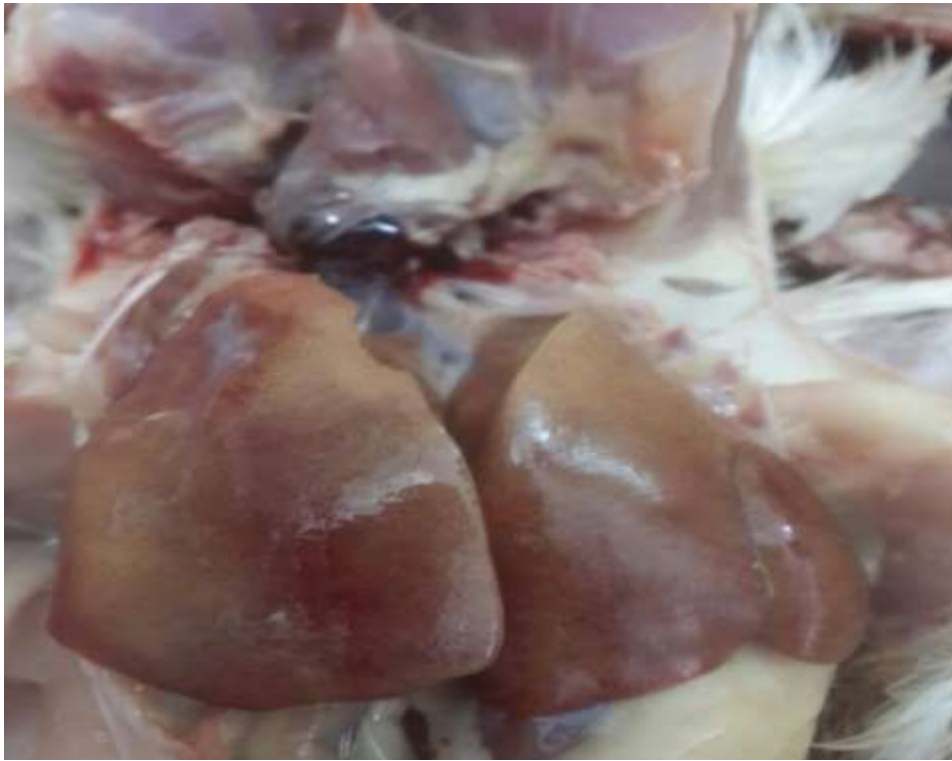Gross lesions:

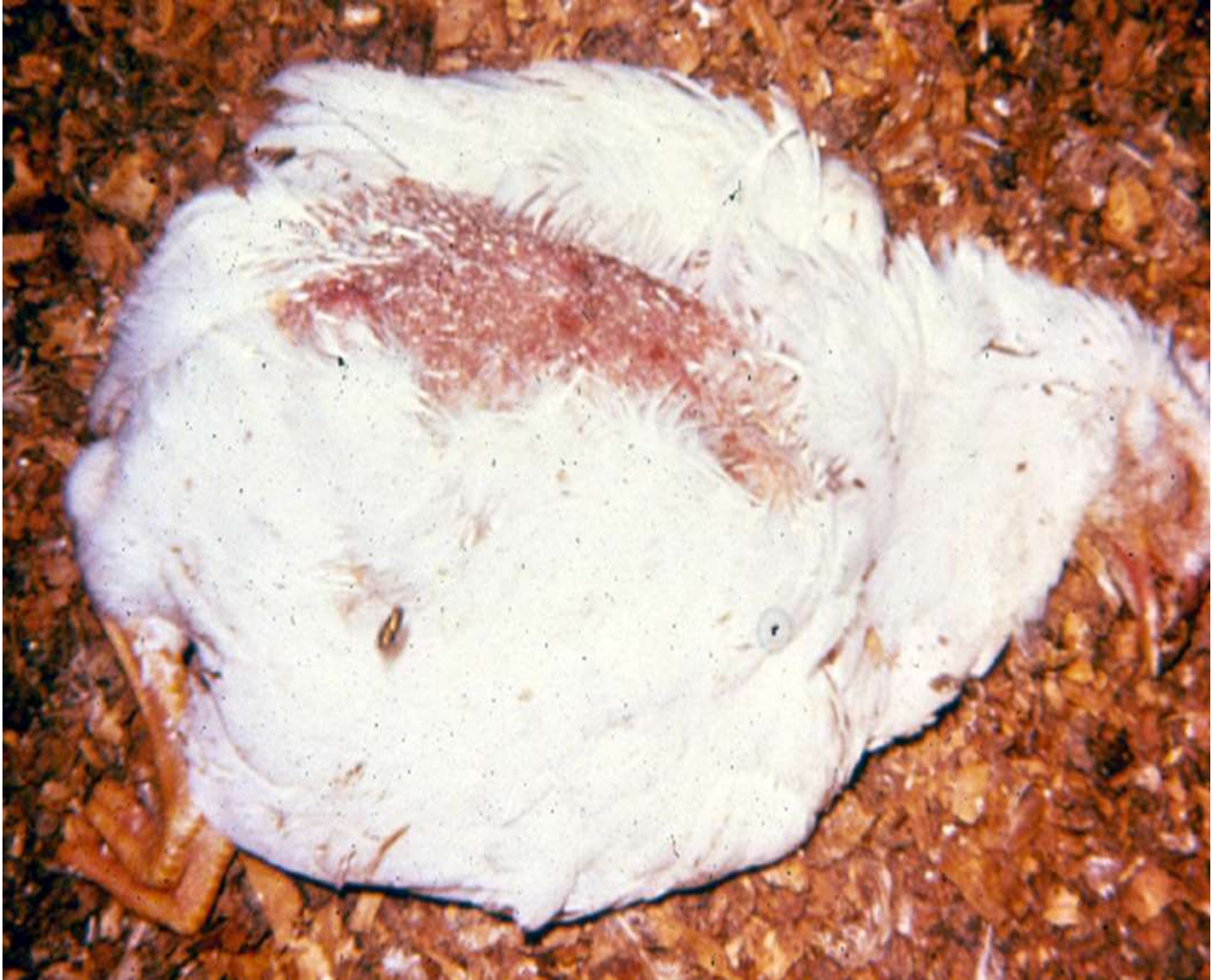generalized congestion, and swollen, yellow, mottled with petechiae and ecchymosis hemorrhages of the liver.



Other changes observed were a discoloured and swollen reticulated friable liver with focal hepatic necrosis, petechial and ecchymotic hemorrhages in heart musculature and other organs, congestion and edema in lungs, and pale kidneys with prominent tubules.

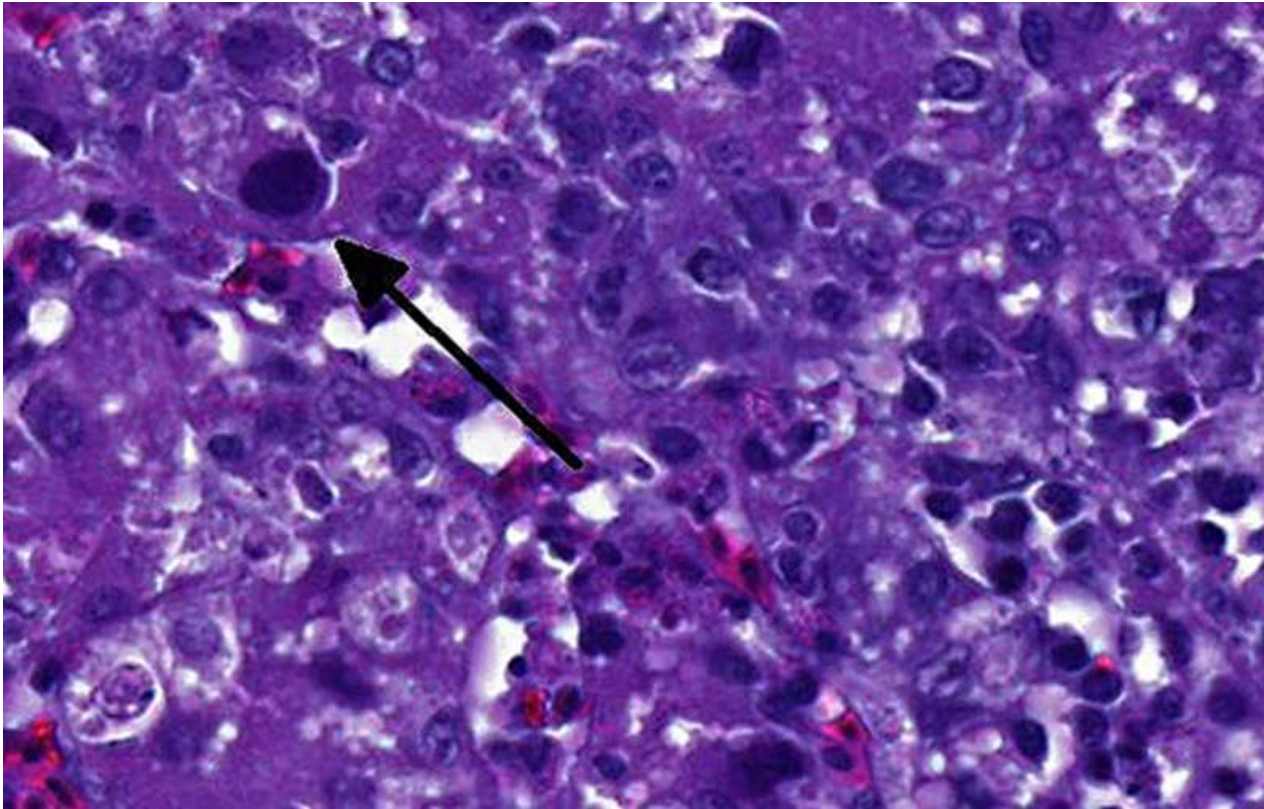


Sudden Death



Histopathologic lesions:

include myocardial edema in the heart with degeneration, necrosis, and mild mononuclear cell infiltration. Basophilic intranuclear inclusion bodies may be present in the liver

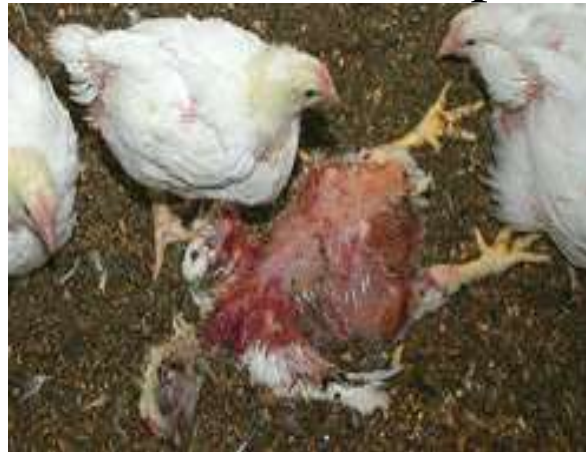

Transmission:

Both vertical and horizontal transmission plays a major role in the spread of IBH/ or HHS .

Vertical transmission: Most outbreaks are initiated by transmission of the virus through the embryonated egg and hens infected with AAV serotypes 4 and 8 that exposed during production will typically shed virus to their progeny for **three to six** weeks until development of immunity.

Horizontal transmission occurs primarily from contact with feces which consider the major factors in the spread of AAV; young chicks in contact with infected chicks can **die** of peracute IBH/HHS.



Air borne transmission of AAV is not an efficient method for spread of virus which lead to contaminated food, water and the environment.

The high titre of AAV in the feces during the acute phase of infection comes via contaminated water and food.

Commercial hatching eggs may be a mechanism of spread of endemic AAV from one area to another.

There is evidence that adenovirus infections can become **latent** and that periods of stress, such as the onset of egg production, will reactivate viral shedding.

The virus present in the litter was reinfesting the birds for long time. It is unknown if some isolates, or serotypes, can be shed over a prolonged period or whether a carrier state may be established in infected chickens.

The virus is generally resistant to disinfectants (ether, chloroform, pH), and high temperatures. **Formaldehyde and iodides work better**. Since adenoviruses are commonly found in healthy poultry, isolation alone does not confirm that they are the cause of a particular problem.

Progeny of high health status breeding flocks appear to be at greater risk, perhaps because they have lower levels of maternal antibody



Isolation and identification of AAV

A 10% suspension of pooled liver, from each of the affected broiler was prepared in Eagle's minimum essential medium (MEM), containing penicillin (200 units/ml), streptomycin (200 ug/ml) and kanamycin (200 units/ml).

After 2 cycles of freezing and thawing the liver suspension was centrifuged at 1000 xg for 20 min and the supernatant was inoculated onto established monolayer cultures of primary CKC cell. When a CPE was observed, it was allowed to progress, usually up to 3 days, to involve 80- 90% of the cells in the monolayer which were then harvested after 2 cycles of freezing and thawing. The resulting suspensions were clarified by low speed centrifugation (1000 xg for 20 min) and stored at -75° C in 1.0 ml aliquots until further use. Cover-slip cultures of CKC in Leighton tubes were inoculated with each viral isolate and, stained with H E for cytopathology.

Diagnosis:

The diagnosis is made by submitting liver samples from affected birds basis of gross lesions, histopathological lesions and virus isolation (frozen).

Positive samples will have large blue inclusion bodies located within the nucleus of the liver cells.

It is critical to isolate the virus from IBH positive samples so that serotyping and/or molecular analysis can be performed.

- Enzyme-linked immunosorbent assay(ELISA) is more sensitive but also will not differentiate by serotype.
- ELISA can be developed for individual serotypes but will not detect the presence of immunity to other serotypes.

Treatment and Prevention: As with many other viral diseases, there **is no treatment**. Antibiotics may help prevent secondary bacterial infections. Sulfonamides are contraindicated if evidence of hematologic disease or immunosuppression is seen.

Good water sanitation (e.g. treatment of drinking water with 0.1% of a 2.5% iodophor solution) appears to be beneficial.

Vaccines against IBH/HP are not commercially available; however, in most countries both live and inactivated vaccines are used to control the syndrome. The AAV serotypes most frequently used to prepare commercial vaccines are **serotypes 4 and 8**. Primary breeders with stringent biosecurity practices sometimes use autogenous inactivated vaccines to ensure the transfer of maternal immunity from breeding flocks to their progeny. In some countries, a live vaccine given via drinking water was developed for breeders between 10–14 wk of age.

In other countries, like Pakistan, and many countries in South America, inactivated vaccines are routinely used to vaccinate breeders and broilers. When breeders are properly vaccinated, antibodies generated by the vaccine are transmitted to the progeny, providing protection against field infections and clinical disease.

Broilers are vaccinated at <10 days of age when their parents either **do not have serotype-specific adenovirus antibodies** or **maternal antibody transmission is irregular** because of improper vaccination procedures that **result** in a extensive number of unvaccinated birds.

Prevention

The condition typically occurs in areas of high poultry density where multi-age operation is traditional.

Control of predisposing immunosuppressive diseases may help limit losses.

Formalin-inactivated oil adjuvant vaccines are reported to be highly effective and are used in areas where the condition is endemic.

The epidemiological factors associated with the development of spread of IBH & HHS are unclear.

Proper disinfections of premises and equipment, restricted entry of visitors, ventilation and proper lightening in the poultry house play a significant role in prevention of the disease.

Key Facts

IBH is a sporadic and infrequent disease caused by avian adenovirus. IBH typically occurs in breeder and broiler flocks less than six weeks of age. All breeds are affected.

Sick birds that do not die will recover. Affected flocks will perform normally after cessation of mortality.

The primary lesion is a pale, enlarged liver with hemorrhages.

Most IBH is caused by vertical transmission and can be prevented by ensuring that breeder flocks are seroconverted prior to the onset of lay.

Endemic AAV can be spread from one area to another by the use of commercial hatching eggs from multiple sources.

In commercial settings, most breeder flocks seroconvert by natural exposure. In rare instances, seroconversion by vaccination or exposure to contaminated bedding material may be required.

Limiting the number of breeding stock suppliers and not **mixing stock from different suppliers will help prevent outbreaks of IBH.**

IBH is more severe in birds with compromised immune systems; therefore, it is important to effectively control **IBD, CAV**, nutritional problems and management factors that cause stress.



*Thank you
for listening*